



Diagnosis and classification of polyarteritis nodosa[☆]



José Hernández-Rodríguez, Marco A. Alba, Sergio Prieto-González, Maria C. Cid*

Vasculitis Research Unit, Department of Autoimmune Diseases, Hospital Clínic, University of Barcelona, Institut d'Investigacions Biomèdiques August Pi i Sunyer (IDIBAPS), Barcelona, Spain

ARTICLE INFO

Article history:

Received 7 October 2013

Accepted 13 November 2013

Keywords:

Polyarteritis nodosa

Vasculitis

Classification

Treatment

ABSTRACT

Polyarteritis nodosa (PAN) is a systemic necrotizing vasculitis preferentially targeting medium-sized arteries and not associated with glomerulonephritis or small vessel involvement. Anti-neutrophil cytoplasmic antibodies are typically negative. PAN may be triggered by viral infections, particularly hepatitis B virus, but remains idiopathic in most cases. Clinical manifestations of PAN are multisystemic. Peripheral nerve and skin are the most frequently affected tissues. Involvement of the gastrointestinal tract, kidneys, heart, and central nervous system is associated with higher mortality. Laboratory abnormalities reveal a prominent acute phase response but are non-specific. Histologic confirmation of vasculitis in medium sized arteries is desirable and biopsies must be obtained from symptomatic organs if feasible. Skin or muscle and nerve are preferred because of higher diagnostic yield and safety. If biopsies are negative or cannot be obtained, visceral angiography, may reveal multiple micro-aneurysms supporting the diagnosis of PAN. Current treatment policy includes high-dose corticosteroids, which are combined with immunosuppressive agents when critical organ involvement or life-threatening complications occur. IV pulse cyclophosphamide in the remission induction phase, later switched to a safer immunosuppressant for remission maintenance is a frequently used therapeutic approach. A recent consensus algorithm for the classification of PAN has attempted to overcome some of the caveats of the 1990 American College of Rheumatology (ACR) classification criteria which have proven to be unsatisfactory, and has also confirmed the low prevalence of PAN compared to other systemic necrotizing vasculitides. European league against rheumatic diseases (EULAR)/ACR endorsed international cooperation to establish new diagnostic/classification criteria is currently under way.

© 2014 Elsevier Ltd. All rights reserved.

Polyarteritis nodosa (PAN) is a primary systemic necrotizing vasculitis predominantly targeting medium-sized arteries defined as the main visceral arteries and their branches [1,2]. Small arteries may also be involved but small vessels, including arterioles, capillaries and venules, are characteristically spared (1). Consequently, glomerulonephritis is not part of the spectrum of PAN. Anti-neutrophil cytoplasmic antibodies (ANCA) are typically negative. These characteristics are useful to differentiate PAN from other systemic necrotizing vasculitis.

PAN may encompass a spectrum of disorders. It may be idiopathic or triggered by specific agents. The most typical is hepatitis B virus (HBV), although other viruses may be occasionally detected.

PAN may be a systemic disease or be confined to single organs or systems [3].

1. Epidemiology

PAN is becoming a rare disease. The reduction in the incidence of PAN may be related to the decrease in HBV infection achieved by widespread vaccination [4]. Moreover, other systemic necrotizing vasculitides (i.e. ANCA – associated vasculitis, cryoglobulinemic vasculitis) are recognized as distinct entities due to increased awareness and improved diagnostic techniques. In the past, systemic necrotizing vasculitis was generally considered as PAN or related variants. The annual incidence of PAN currently ranges from 0 to 1.6 cases/million inhabitants in European countries [5,6] and its prevalence is about 31 cases/million [7,8]. PAN affects patients of any gender, age, or ethnic background. The peak incidence occurs in the 5th–6th decades of life [5–8]. Before vaccination against HBV was available, more than one-third of adults with PAN were infected by HBV. Currently, less than 5% of patients with PAN are HBV-infected in developed countries [7].

[☆] Supported by Ministerio de Economía y Competitividad (SAF 11/30073). Marco A Alba was supported by Consejo Nacional de Ciencia y Tecnología (CONACYT), México and by the Agencia de Gestió d'Ajuts Universitaris i de Recerca (AGAUR) (Generalitat de Catalunya).

* Corresponding author. Department of Autoimmune Diseases, Hospital Clínic, Villarroel 170, 08036 Barcelona, Spain. Tel.: +34 93 2275774; fax: +34 93 2271707. E-mail address: mccid@clinic.ub.es (M.C. Cid).

2. Pathogenesis

PAN was initially considered as an immune-complex related disease based on the development of necrotizing arteritis in animal models of immune-complex-mediated injury [9]. However, glomerulonephritis, a characteristic immune-complex mediated lesion is not associated with PAN. Moreover, complement consumption, common in other immune-complex mediated diseases such as cryoglobulinemic vasculitis or systemic lupus erythematosus is unusual. The presence of dendritic cells and the abundance of CD4+ lymphocytes in vascular inflammatory infiltrates suggest that antigen-specific T-cell mediated immune responses may also play a role in the pathogenesis of vascular inflammation in PAN [10]. Unlike other systemic vasculitides which remain idiopathic or are considered truly autoimmune, PAN has several identified triggers. HBV is the most common and better characterized trigger of PAN and the recognition of the etiopathogenic role of HBV in HBV-associated PAN has important therapeutic implications. Hepatitis C virus (HCV), human immunodeficiency virus (HIV), cytomegalovirus and parvovirus B19 are also putative triggers of PAN lesions in some patients [4,11–14].

3. Clinical manifestations

Due to the ubiquity of blood vessels, the occlusion or rupture of the inflamed arteries may produce tissue ischemia or hemorrhage in a variety of organs and systems. Consequently PAN may generate

a wide constellation of clinical manifestations. Symptoms may develop indolently but acute, life-threatening complications may appear abruptly. Clinical manifestations are summarized in Table 1. These include non-specific constitutional manifestations such as malaise, weight loss, fever, arthralgia and myalgia, present in a high proportion of patients and symptoms derived from dysfunction or damage of the target organs [4,6,15].

The peripheral nervous system and the skin are the most frequently involved territories [4,15]. Mononeuritis multiplex is the most common neurological manifestation although symmetrical polyneuropathy may also occur. Cutaneous features include purpura, livedoid lesions, subcutaneous nodules and necrotic ulcers [4,15]. Gastrointestinal tract and kidneys are frequently involved. Gastrointestinal manifestations convey a remarkable morbidity and mortality [16]. Renal involvement in PAN consists of tissue infarction or hematoma, usually produced by rupture of renal microaneurysms [15,16]. Kidney infarcts may be clinically silent or produce micro or macrohematuria and mild to moderate proteinuria (Fig. 1). PAN does not cause glomerulonephritis. Hypertension secondary to intrarenal artery involvement is frequent [4,6,15]. Kidney function is usually spared but multiple renal infarcts or uncontrolled hypertension may decrease renal function [4,15]. Kidney failure is uncommon.

Interestingly, HBV-associated PAN produces more frequently peripheral neuropathy and hypertension and less frequently cutaneous lesions than idiopathic PAN. It also has higher severity as assessed by the Birmingham vasculitis activity score (BVAS) [4].

4. Laboratory features

There are no laboratory abnormalities specific for PAN. Erythrocyte sedimentation rate, C-reactive protein and other acute phase reactants are commonly elevated. Chronic anemia and leukocytosis are frequently present [4,15]. Hypereosinophilia may be occasionally seen but, when present, eosinophilic granulomatosis with polyangiitis (Churg–Strauss) (EGPA) must be ruled out [17]. Serologies for HBV, HCV, and other chronic viral infections are useful to diagnose viral-associated PAN with the ensuing therapeutic implications [4,15]. ANCA are typically negative and their detection in the context of necrotizing vasculitis strongly points towards the diagnosis of other systemic vasculitis commonly associated with their presence, such as microscopic polyangiitis (MPA), granulomatosis with polyangiitis (Wegener's) (GPA) or EGPA [17,18].

Table 1
Main clinical manifestations of patients with polyarteritis nodosa [4,15,16].

	Frequency (%)
Systemic symptoms	
Fever	31–69
Weight loss	16–69
Myalgias	30–59
Arthralgias	44–58
Cutaneous involvement	28–58
Nodules	17
Livedo	16
Neurologic manifestations	40–79
Mononeuritis multiplex	38–72
Peripheral neuropathy	74
Central nervous system	2–28
Cranial nerve palsy	<2
Gastrointestinal tract involvement	14–44
Abdominal pain	36–97
Nausea/vomiting ^a	12/38 (32%)
Diarrhea ^a	6/38 (16%)
Hematochezia/melena	3–5
Hematemesis ^a	3/38 (8%)
Esophageal ulceration ^a	5/38 (13%)
Gastroduodenal ulceration ^a	12/38 (32%)
Colorectal ulceration ^a	2/38 (5%)
Surgical abdomen/peritonitis	14–32
Urologic and renal involvement	8–66
Hypertension (recent onset)	10–63
Hematuria	15
Proteinuria	22
Orchitis/epididymitis	2–18
Ophthalmologic manifestations^b	3–44
Cardiac disease	4–30
Respiratory tract disease^c	
Pleuritis	5

^a % Referred to a series of 38 PAN patients with gastrointestinal manifestations [16].

^b Includes retinal vasculitis, retinal detachment and other findings such as cotton-wool spots.

^c In general, not related to lung involvement but secondary to cardiac or renal disease.

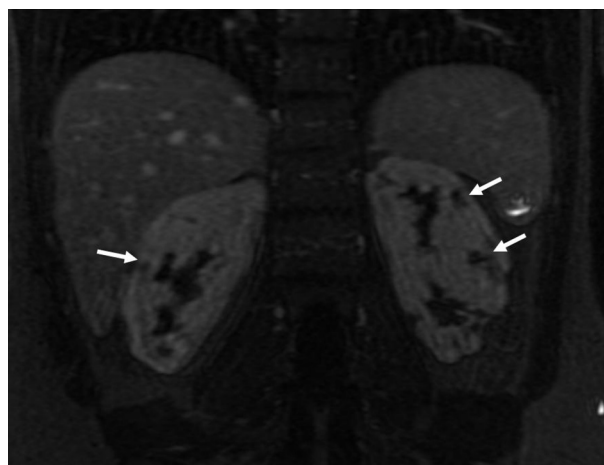


Fig. 1. Kidney infarcts (arrows) in a patient with polyarteritis nodosa and hypertension (nuclear magnetic resonance).

5. Histopathology

Vascular inflammatory lesions are characteristically segmental and predominate in branching points [2]. Inflammatory infiltrates are typically mixed and include lymphocytes, macrophages, and variable numbers of neutrophils and eosinophils [2]. Granulomas and giant cells are usually absent. Fibrinoid necrosis is frequently seen in active lesions and neutrophils are more frequently present in vessels with fibrinoid necrosis [2,10]. At later stages, lymphocyte and macrophage infiltration usually predominates and neoangiogenesis becomes apparent [2,10,19] (Fig. 2). In advanced lesions, vascular remodeling leads to the development of intimal hyperplasia and diffuse fibrotic changes within the vessel wall [2,10,19]. Thrombosis may also contribute to vascular occlusion. Severe vessel wall injury may result in the formation of microaneurysms [2]. Vessels with acute necrotizing lesions typically coexist with others with fibrotic or healing changes, representing different stages of the inflammatory process [2,10,19].

6. Diagnosis and classification

6.1. Biopsy findings

PAN is a multisystemic disorder producing a variety of symptoms common to other conditions (i.e. infection, malignancy). The histopathologic demonstration of vascular inflammation in medium-sized or small arteries is crucial to sustain the diagnosis of vasculitis and excluding other disorders. In order to achieve the maximal diagnostic yield, biopsies must be performed to symptomatic sites (e.g. muscle, sural nerve, skin, or testicle). When various organs are involved, the less aggressive approach (i.e. skin or muscle biopsies) is preferred. In a large series of patients with PAN, combined muscle and nerve biopsies in symptomatic patients provided histologic confirmation of vasculitis in 83% whereas isolated muscle biopsies demonstrated vascular inflammation in 65% [4]. In cases in which biopsies of muscle and nerve are blindly performed, vasculitis can be seen in up to one-third [2,15,20]. Testicular biopsy was advised in the past based on that testicles are frequently involved in necropsy studies. However, blind testicular biopsies do not have a suitable diagnostic yield and should be only performed when testicles are clinically involved or biopsies from other symptomatic territories have been negative [20]. Due to the potential development of microaneurysms and the potential of hemorrhage, ultrasonography controlled kidney and liver biopsies, should be only performed when other approaches have been

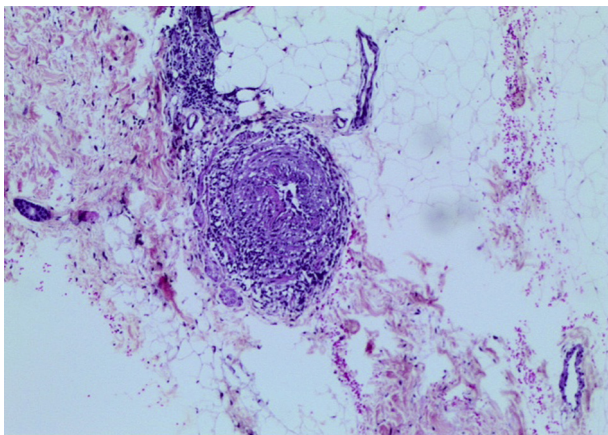


Fig. 2. Typical histopathologic findings of polyarteritis nodosa: subcutaneous tissue artery with mixed inflammatory infiltrate in a biopsy of a livedoid skin lesion.

unsuccessful [20]. PAN or other necrotizing vasculitis can also be unexpectedly diagnosed in temporal artery biopsies from patients with clinical suspicion of giant-cell arteritis [21]. Although the main temporal arteries may be affected, involvement of the surrounding branches is more commonly seen. A systemic necrotizing vasculitis must be always ruled out when inflammation of the temporal artery branches with a spared temporal artery is observed in a temporal artery biopsy [21].

6.2. Imaging findings

Visceral angiography may be performed in situations in which PAN is highly suspected and histologic diagnosis of vasculitis cannot be achieved, or in patients predominantly experiencing symptoms suggestive of abdominal, renal or cardiac involvement. Typical arteriographic lesions in PAN are arterial saccular or fusiform microaneurysms (1–5 mm in diameter), which usually coexist with stenotic lesions, predominantly in kidney, mesenteric and hepatic artery branches (Fig. 3). When characteristic angiographic changes are detected by an experienced radiologist, in the appropriate clinical context, the diagnosis of PAN can be established, even in absence of histologic confirmation [15,17,20]. It must be kept in mind that conditions other than PAN, particularly structural vasculopathies, may lead to multiple aneurysm formation [22].

6.3. Definition and classification criteria

The histopathologic demonstration of necrotizing arteritis is not sufficient to classify a patient into the PAN category and additional clinical and laboratory data are necessary. The American College of Rheumatology (ACR) proposed classification criteria for PAN in 1990 considering clinical, laboratory (including detection of HBV), angiographic and histologic features [23]. As knowledge has progressed it has become apparent that the ACR criteria have important limitations. ACR criteria did not consider MPA as a distinct entity to be differentiated from PAN and did not take into

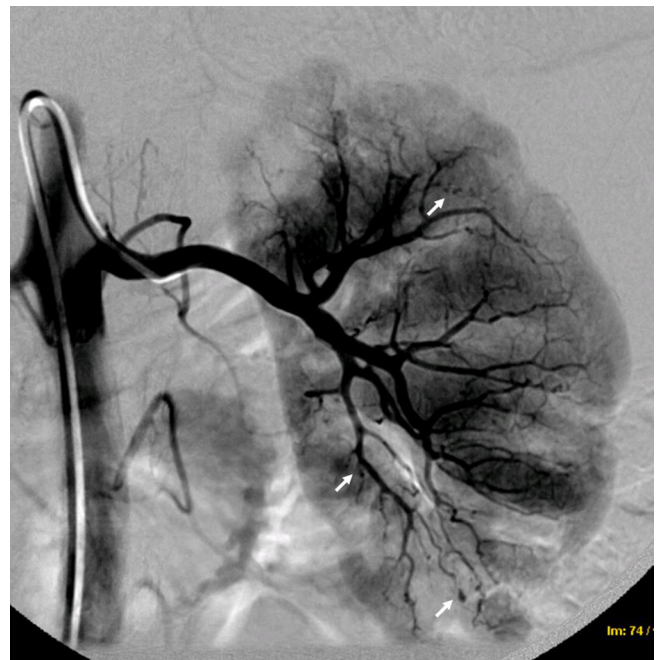


Fig. 3. Kidney angiography showing irregular perfusion with, arterial stenosis, amputations and microaneurysms (arrows) in a patient with polyarteritis nodosa.

consideration ANCA testing. In the 1994 Chapel Hill Consensus Conference, MPA was differentiated from PAN, and was defined as a small to medium-sized vessel vasculitis typically presenting with necrotizing glomerulonephritis and pulmonary capillaritis [1]. The absence of pulmonary and glomerular capillary involvement in PAN has been useful in distinguishing this entity from ANCA-associated vasculitides which frequently involve pulmonary capillaries and glomeruli. The negativity of ANCA in PAN has been emphasized in the updated 2012 Chapel Hill consensus definitions [1].

Several studies have demonstrated that many patients, who met ACR classification criteria for PAN, after being reevaluated, did not meet the definition of PAN according to the Chapel Hill Consensus Conference [5,6,17]. Therefore, the incidence of PAN has been overestimated in studies performed before the publication of the Chapel Hill definition. Reasons for re-definition were the presence of glomerulonephritis, small vessel involvement, ANCA positivity, detection of cryoglobulins or viral infection. Consequently, many patients previously diagnosed with PAN may be re-categorized as having MPA or infection-related vasculitis.

A consensus algorithm for the classification of PAN and other necrotizing vasculitides, has been proposed by combining ACR and Chapel Hill criteria, ANCA testing and surrogate markers of vascular inflammation, including clinical, laboratory, neurophysiologic and imaging tests (Fig. 4) [17]. This algorithm has been already used in a large epidemiologic study including different vasculitides and has definitively confirmed the low prevalence of PAN [17]. In a survey of 949 patients with systemic vasculitis, HBV positivity, peripheral neuropathy, arteriographic abnormalities, as well as absence of ENT manifestations glomerulonephritis and cryoglobulins were predictive of PAN diagnosis [24]. Existing classification criteria for systemic vasculitis, and particularly PAN, are not satisfactory and

currently, there is an international collaborative effort aimed to establish better diagnostic and classification criteria [26,27].

7. Disease course and prognosis

Contrarily to MPA or GPA which are typically multi-relapsing diseases, PAN has been classically considered a monophasic disease with a relapse rate inferior to 10%. However, recent studies have shown a relapse rate higher than previously reported, and similar to that seen in patients with MPA [4,6,25,28].

The prognosis of PAN depends on the organs involved. The French Vasculitis Study Group (FVSG) proposed the Five Factor Score (FFS), a prognosis index considering the following items: presence of severe gastrointestinal tract disease (defined as bleeding, perforation, infarction, or pancreatitis), renal involvement consisting of serum creatinine ≥ 1.58 mg/dL or proteinuria (≥ 1 g/day), cardiac disease (infarction or heart failure), and central nervous system involvement. When present, each of those is given a score of 1 [29]. The 5-year mortality of PAN patients with FFS = 0 was 12%, for those with FFS = 1 was 26%, and when FFS was ≥ 2 mortality was 46%. The overall 7-year survival for PAN is 79% [29]. FFS has been recently re-visited and age >65 years has been also considered as a poor prognosis indicator [30].

8. Special forms

8.1. Localized PAN

As opposed to systemic PAN, localized PAN is restricted to single organs or systems [3]. The most frequent is cutaneous PAN [31]. Patients with cutaneous PAN may have livedoid lesions, painful

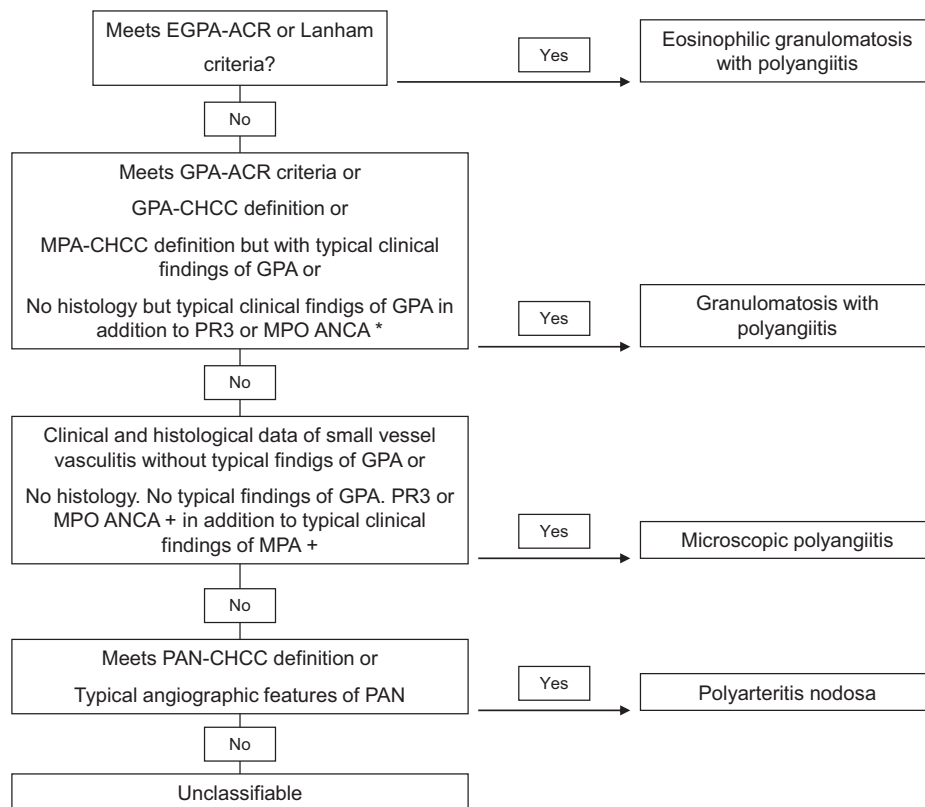


Fig. 4. Consensus algorithm proposed by Watts et al. for the classification of EGPA (Churg–Strauss), GPA (Wegener’s), MPA, and PAN (adapted from Ref. [17]). *Typical findings of GPA include but not limited to imaging evidence of fixed pulmonary infiltrated, nodules or cavitations, bronchial stenoses, bloody nasal discharge and crusting, nasal ulceration, chronic sinusitis, otitis media or mastoiditis, retro-orbital mass, subglottic stenosis or saddle-nose deformity. +Typical findings of MPA include alveolar hemorrhage and hematuria associated with red cell casts or 10% dysmorphic erythrocytes or proteinuria.

nodules or necrotic ulcers but lack visceral involvement. Cutaneous PAN is associated to lower mortality and severity but lesions are less responsive to conventional treatments. Peripheral nerve restricted PAN and PAN limited to striated muscles, particularly at the lower extremities with no visceral involvement have been also reported [1,31–33].

Occasionally, localized PAN lesions can be discovered in surgical specimens, including appendix, gallbladder, testicles and other organs from patients with local symptoms or complications [2,34,35]. These patients need to be thoroughly evaluated and carefully followed to exclude the existence of a systemic vasculitis presenting with a surgery-requiring complication or mass in the removed organ as the most prominent manifestation. In truly focal forms excision is in most instances curative [2,34,35].

8.2. PAN in childhood

PAN may occur in pediatric patients [28]. Clinical manifestations, complications and course are similar to PAN in adults (Fig. 5). Classification criteria for PAN in children have been recently established [36,37]. PAN may sometimes develop in children with Mediterranean familial fever.

9. Treatment

The level of evidence supporting therapeutic decisions in PAN is low [38]. As mentioned, grounds on which patients with necrotizing vasculitis have been classified as PAN have evolved over the years. The existing randomized clinical trials have been performed on mixed cohorts of patients with PAN, EGPA or MPA [39,40]. The distribution of the involved organs and disease progression are the two principal determinants for treating patients with PAN. Current therapeutic approaches consider treating mild forms of primary PAN (with FFS = 0) with corticosteroids only; typically, prednisone or prednisolone at doses of 1 mg/kg/day with subsequent tapering when remission is achieved [39,40]. When prednisone cannot be tapered below 15–20 mg/day without recurrence, the addition of another immunosuppressive agent is considered. In life-threatening situations or rapidly progressive

disease, therapy with IV methyl-prednisolone pulses (1000 mg/day for 3 days) may be tried. In the presence of critical organ involvement indicated by an FFS ≥ 1 , immunosuppressants are given in addition to prednisone [40]. Cyclophosphamide is used at doses of 2 mg/kg/day orally or as monthly intravenous doses of 0.6 g/m² for 6–12 months [34,40]. Monthly pulse intravenous administration is preferred to daily oral cyclophosphamide because of its better safety profile. Currently, and as an extrapolation from the evidence obtained from trials performed with patients with MPA and granulomatosis with polyangiitis cyclophosphamide is recommended to induce remission and a safer immunosuppressive agent such as azathioprine or methotrexate is advised to maintain remission [18]. Cyclophosphamide treatment beyond 12 months is not recommended. Angiographic abnormalities can regress after treatment [16]. Surgery may be required for some disease complications, such as perforation/rupture, ischemia or hemorrhage of the gastrointestinal organs or kidneys [16].

In patients with HBV-associated vasculitis, combination of short corticosteroid treatment with plasma exchanges and anti-viral therapy (currently lamivudine or adefovir) may be effective in controlling disease activity and in facilitating viral seroconversion. The control of the viremia also helps in preventing the development of long-term hepatic complications of HBV infection [4,27]. Contrarily to idiopathic or primary PAN, relapses are rare in HBV-related PAN and never occur when viral replication has ceased and seroconversion has been achieved [16]. Although the existing experience is more limited, the same approach (short glucocorticoid treatment followed by specific anti-viral therapy) may be suitable for other virus associated PAN.

10. Concluding remarks

As the knowledge progresses, PAN, the first described systemic necrotizing vasculitis, has become a rare condition. International efforts are necessary to establish robust diagnostic and classification criteria, as well to improve treatment options for these patients.

References

- [1] Jennette JC, Falk RJ, Bacon PA, Basu N, Cid MC, Ferrario F, et al. 2012 Revised international Chapel Hill consensus conference nomenclature of vasculitides. *Arthritis Rheum* 2013;65:1–11.
- [2] Lie JT. Systemic and isolated vasculitis. A rational approach to classification and pathologic diagnosis. *Pathol Annu* 1989;24:25–114.
- [3] Hernández-Rodríguez J, Hoffman GS. Updating single-organ vasculitis. *Curr Opin Rheumatol* 2012;24:38–45.
- [4] Pagnoux C, Seror R, Henegar C, Mahr A, Cohen P, Le Guern V, et al., French Vasculitis Study Group. Clinical features and outcomes in 348 patients with polyarteritis nodosa: a systematic retrospective study of patients diagnosed between 1963 and 2005 and entered into the French Vasculitis Study Group Database. *Arthritis Rheum* 2010;62:616–26.
- [5] González-Gay MA, García-Porrúa C, Guerrero J, Rodríguez-Ledo P, Llorca J. The epidemiology of the primary systemic vasculitides in northwest Spain: implications of the Chapel Hill consensus conference definitions. *Arthritis Rheum* 2003;49(3):388–93.
- [6] Selga D, Mohammad A, Sturfelt G, Segelmark M. Polyarteritis nodosa when applying the Chapel Hill nomenclature – a descriptive study on ten patients. *Rheumatology (Oxford)* 2006;45(10):1276–81.
- [7] Mahr A, Guillemin L, Poissonnet M, Ayme S. Prevalences of polyarteritis nodosa, microscopic polyangiitis, Wegener's granulomatosis, and Churg-Strauss syndrome in a French urban multiethnic population in 2000: a capture-recapture estimate. *Arthritis Rheum* 2004;51(1):92–9.
- [8] Mohammad AJ, Jacobsson LT, Mahr AD, Sturfelt G, Segelmark M. Prevalence of Wegener's granulomatosis, microscopic polyangiitis, polyarteritis nodosa and Churg Strauss syndrome within a defined population in southern Sweden. *Rheumatology (Oxford)* 2007;46(8):1329–37.
- [9] Fauci AS, Haynes B, Katz P. The spectrum of vasculitis: clinical, pathologic, immunologic and therapeutic considerations. *Ann Intern Med* 1978;89:660–76.
- [10] Cid MC, Grau JM, Casademont J, Campo E, Coll-Vinent B, López-Soto A, et al. Immunohistochemical characterization of inflammatory cells and immunologic

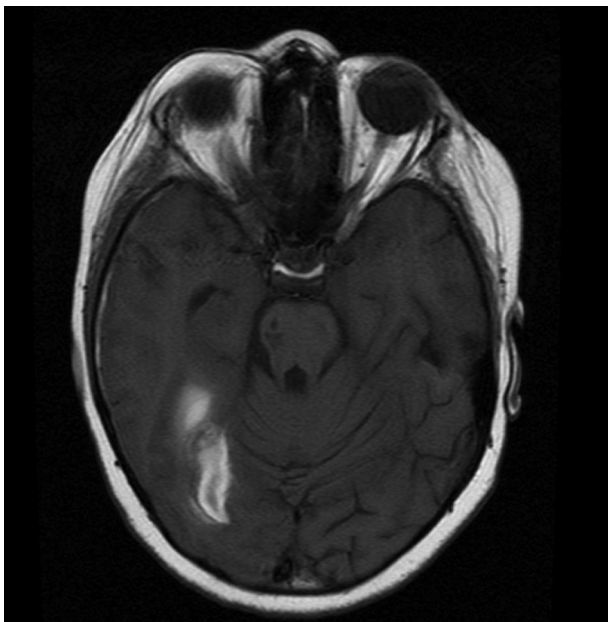


Fig. 5. Brain hemorrhagic infarct in a child with polyarteritis nodosa.

- activation markers in muscle and nerve biopsy specimens from patients with systemic polyarteritis nodosa. *Arthritis Rheum* 1994;37(7):1055–61.
- [11] Pagnoux C, Cohen P, Guillevin L. Vasculitides secondary to infections. *Clin Exp Rheumatol* 2006;24(Suppl. 41):S71–81.
- [12] Font C, Miró O, Pedrol E, Masanés F, Coll-Vinent B, Casademont J, et al. Polyarteritis nodosa in human immunodeficiency virus infection: report of four cases and review of the literature. *Br J Rheumatol* 1996;35:796–9.
- [13] Corman LC, Dolson DJ. Polyarteritis nodosa and parvovirus B19 infection. *Lancet* 1992;339:491.
- [14] Calabrese LH. Vasculitis and infection with the human immunodeficiency virus. *Rheum Dis Clin North Am* 1991;17:131–47.
- [15] Lhote F, Cohen P, Guillevin L. Polyarteritis nodosa, microscopic polyangiitis and Churg-Strauss syndrome. *Lupus* 1998;7(4):238–58.
- [16] Pagnoux C, Mahr A, Cohen P, Guillevin L. Presentation and outcome of gastrointestinal involvement in systemic necrotizing vasculitides: analysis of 62 patients with polyarteritis nodosa, microscopic polyangiitis, Wegener granulomatosis, Churg-Strauss syndrome, or rheumatoid arthritis-associated vasculitis. *Medicine (Baltimore)* 2005;84(2):115–28.
- [17] Watts R, Lane S, Hanslik T, Hauser T, Hellmich B, Koldingsnes W, et al. Development and validation of a consensus methodology for the classification of the ANCA-associated vasculitides and polyarteritis nodosa for epidemiological studies. *Ann Rheum Dis* 2007;66(2):222–7.
- [18] Guillevin L, Lhote F, Amouroux J, Gherardi R, Callard P, Casassus P. Anti-neutrophil cytoplasmic antibodies, abnormal angiograms and pathological findings in polyarteritis nodosa and Churg-Strauss syndrome: indications for the classification of vasculitides of the polyarteritis Nodosa Group. *Br J Rheumatol* 1996;35(10):958–64.
- [19] Coll-Vinent B, Cebrián M, Cid MC, Font C, Esparza J, Juan M, et al. Dynamic pattern of endothelial cell adhesion molecule expression in muscle and perineural vessels from patients with classic polyarteritis nodosa. *Arthritis Rheum* 1998;41:435–44.
- [20] Albert DA, Rimon D, Silverstein MD. The diagnosis of polyarteritis nodosa. I. A literature-based decision analysis approach. *Arthritis Rheum* 1988;31(9):1117–27.
- [21] Esteban MJ, Font C, Hernández-Rodríguez J, Valls-Solé J, Sanmartí R, Cardellach F, et al. Small-vessel vasculitis surrounding a spared temporal artery: clinical and pathological findings in a series of twenty-eight patients. *Arthritis Rheum* 2001;44(6):1387–95.
- [22] Molloy ES, Langford CA. Vasculitis mimics. *Curr Opin Rheumatol* 2008;20:29–34.
- [23] Lightfoot Jr RW, Michel BA, Bloch DA, Hunder GG, Zvaifler NJ, Mc Shane DJ, et al. The American College of Rheumatology 1990 criteria for the classification of polyarteritis nodosa. *Arthritis Rheum* 1990;33(8):1088–93.
- [24] Henegar C, Pagnoux C, Puéchal X, Zucker JD, Bar-Hen A, Le Guern V, et al., French Vasculitis Study Group. A paradigm of diagnostic criteria for polyarteritis nodosa: analysis of a series of 949 patients with vasculitides. *Arthritis Rheum* 2008;58:1528–38.
- [25] Gayraud M, Guillevin L, le Toumelin P, Cohen P, Lhote F, Casassus P, et al., French Vasculitis Study Group. Long-term followup of polyarteritis nodosa, microscopic polyangiitis, and Churg-Strauss syndrome: analysis of four prospective trials including 278 patients. *Arthritis Rheum* 2001;44:666–75.
- [26] Basu N, Watts R, Bajema I, Baslund B, Bley T, Boers M, et al. EULAR points to consider in the development of classification and diagnostic criteria in systemic vasculitis. *Ann Rheum Dis* 2010;69:1744–50.
- [27] Craven A, Robson J, Ponte C, Grayson PC, Suppiah R, Judge A, et al. ACR/EULAR-endorsed study to develop diagnostic and classification criteria for vasculitis (DCVAS). *Clin Exp Nephrol* 2013;17:619–21.
- [28] Eleftheriou D, Dillon MJ, Tullus K, Marks SD, Pilkington CA, Roebuck DJ, et al. Systemic polyarteritis nodosa in the young: a single-center experience over thirty-two years. *Arthritis Rheum* 2013;65:2476–85.
- [29] Bourgarit A, Le Toumelin P, Pagnoux C, Cohen P, Mahr A, Le Guern V, et al. Deaths occurring during the first year after treatment onset for polyarteritis nodosa, microscopic polyangiitis, and Churg-Strauss syndrome: a retrospective analysis of causes and factors predictive of mortality based on 595 patients. *Medicine (Baltimore)* 2005;84(5):323–30.
- [30] Guillevin L, Pagnoux C, Seror R, Mahr A, Mouthon L, Le Toumelin P, French Vasculitis Study Group (FVSG). The five-factor score revisited: assessment of prognoses of systemic necrotizing vasculitides based on the French Vasculitis Study Group (FVSG) cohort. *Medicine (Baltimore)* 2011;90:19–27.
- [31] Segelmark M, Selga. The challenge of managing patients with polyarteritis nodosa. *Curr Opin Rheumatol* 2007;19:33–8.
- [32] Collins MP, Dyck PJ, Gronseth GS, Guillevin L, Hadden RD, Heuss D, et al., Peripheral Nerve Society. Peripheral Nerve Society guideline on the classification, diagnosis, investigation, and immunosuppressive therapy of non-systemic vasculitic neuropathy: executive summary. *J Peripher Nerv Syst* 2010;15:176–84.
- [33] García F, Pedrol E, Casademont J, Mellado B, Córdoba R, Cid M, et al. Polyarteritis nodosa confined to calf muscles. *J Rheumatol* 1992;19:303–5.
- [34] Hernández-Rodríguez J, Tan CD, Koenig CL, Khasnis A, Rodríguez ER, Hoffman GS. Testicular vasculitis: findings differentiating isolated disease from systemic disease in 72 patients. *Medicine (Baltimore)* 2012;91:75–85.
- [35] Hernández-Rodríguez J, Tan CD, Rodríguez ER, Hoffman GS. Gynecologic vasculitis: an analysis of 163 patients. *Medicine (Baltimore)* 2009;88:169–81.
- [36] Ruperto N, Ozen S, Pistorio A, Dolezalova P, Brogan P, Cabral DA, et al. EULAR/PRINTO/PRES criteria for Henoch-Schönlein purpura, childhood polyarteritis nodosa, childhood Wegener granulomatosis, and childhood Takayasu arteritis. Ankara 2008. Part I: introduction and methods. *Ann Rheum Dis* 2010;69:790–7.
- [37] Ozen S, Pistorio A, Iusan SM, Bakaloglu A, Herlin T, Brik R, et al., Paediatric Rheumatology International Trials Organisation (PRINTO). EULAR/PRINTO/PRES criteria for Henoch-Schönlein purpura, childhood polyarteritis nodosa, childhood Wegener granulomatosis and childhood Takayasu arteritis: Ankara 2008. Part II: final classification criteria. *Ann Rheum Dis* 2010;69:798–806.
- [38] Mukhtyar C, Guillevin L, Cid MC, Dasgupta B, de Groot K, Gross W, et al., European Vasculitis Study Group. EULAR recommendations for the management of primary small and medium vessel vasculitis. *Ann Rheum Dis* 2009;68:310–7.
- [39] Ribi C, Cohen P, Pagnoux C, Mahr A, Arène JP, Puéchal X, et al., French Vasculitis Study Group. Treatment of polyarteritis nodosa and microscopic polyangiitis without poor-prognosis factors: a prospective randomized study of one hundred twenty-four patients. *Arthritis Rheum* 2010;62:1186–97.
- [40] Guillevin L, Cohen P, Mahr A, Arène JP, Mouthon L, Puéchal X, et al. Treatment of polyarteritis nodosa and microscopic polyangiitis with poor prognosis factors: a prospective trial comparing glucocorticoids and six or twelve cyclophosphamide pulses in sixty-five patients. *Arthritis Rheum* 2003;49:93–100.